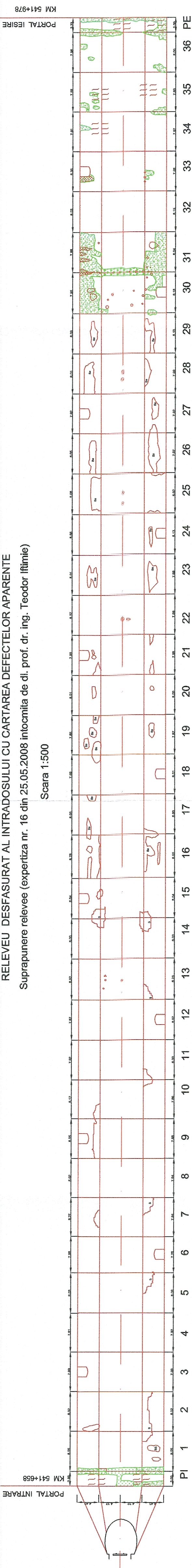


RELEVU DE SFASURAT AL INTRADOSULUI CU CARTAREA DEFECTELOR APARENTE
Suprapunere relevee (expertiza nr. 16 din 25.05.2008 intocmita de dl. prof. dr. ing. Teodor Iftimie)

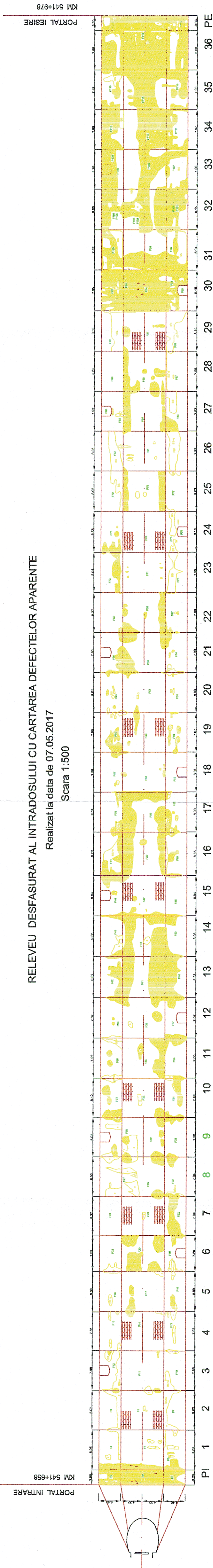
Scara 1:500



RELEVU DE SFASURAT AL INTRADOSULUI CU CARTAREA DEFECTELOR APARENTE

Realizat la data de 07.05.2017

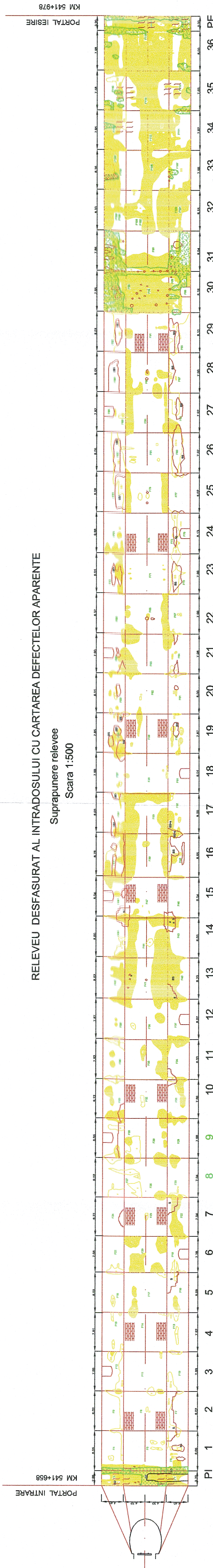
Scara 1:500



RELEVU DE SFASURAT AL INTRADOSULUI CU CARTAREA DEFECTELOR APARENTE

Suprapunere relevee

Scara 1:500



LEGENDA

- Cmp
- Pml
- Pml
- Pml
- Pml
- Pml
- Pml
- Pml
- Pml
- Pml
- Pml
- Pml
- Pml
- Pml
- Pml
- Pml
- Pml
- Pml
- Pml
- Pml
- Pml
- Pml
- Pml
- Pml
- Pml
- Pml
- Pml
- Pml
- Pml
- Pml
- Pml
- Pml
- Pml
- Pml
- Pml
- Pml
- Pml
- Pml
- Pml
- Pml
- Pml
- Pml
- Pml
- Pml
- Pml
- Pml
- Pml
- Pml
- Pml
- Pml
- Pml
- Pml
- Pml
- Pml
- Pml
- Pml
- Pml
- Pml
- Pml
- Pml
- Pml
- Pml
- Pml
- Pml
- Pml
- Pml
- Pml
- Pml
- Pml
- Pml
- Pml
- Pml
- Pml
- Pml
- Pml
- Pml
- Pml
- Pml
- Pml
- Pml
- Pml
- Pml
- Pml
- Pml
- Pml
- Pml
- Pml
- Pml
- Pml
- Pml
- Pml
- Pml
- Pml
- Pml
- Pml
- Pml
- Pml
- Pml
- Pml
- Pml
- Pml
- Pml
- Pml
- Pml
- Pml
- Pml
- Pml
- Pml
- Pml
- Pml
- Pml
- Pml
- Pml
- Pml
- Pml
- Pml
- Pml
- Pml
- Pml
- Pml
- Pml
- Pml
- Pml
- Pml
- Pml
- Pml
- Pml
- Pml
- Pml
- Pml
- Pml
- Pml
- Pml
- Pml
- Pml
- Pml
- Pml
- Pml
- Pml
- Pml
- Pml
- Pml
- Pml
- Pml
- Pml
- Pml
- Pml
- Pml
- Pml
- Pml
- Pml
- Pml
- Pml
- Pml
- Pml
- Pml
- Pml
- Pml
- Pml
- Pml
- Pml
- Pml
- Pml
- Pml
- Pml
- Pml
- Pml
- Pml
- Pml
- Pml
- Pml
- Pml
- Pml
- Pml
- Pml
- Pml
- Pml
- Pml
- Pml
- Pml
- Pml
- Pml
- Pml
- Pml
- Pml
- Pml
- Pml
- Pml
- Pml
- Pml
- Pml
- Pml
- Pml
- Pml
- Pml
- Pml
- Pml
- Pml
- Pml
- Pml
- Pml
- Pml
- Pml
- Pml
- Pml
- Pml
- Pml
- Pml
- Pml
- Pml
- Pml
- Pml
- Pml
- Pml
- Pml
- Pml
- Pml